

Renal Resistive Index: is it Predictor of Renal Vascular and Target Organ Damage in Essential Hypertension?

S. Bogdanovska, K. Zafirovska, S. Dzikova, Lj. Lozanche, B. Gerasimovska-Kitanovska, G. Severova-Andreevska, M. Milovancheva-Popovska, A. Asani

Department of Nephrology, Clinical Center-Skopje, Medical Faculty, University "Sts Cyril & Methodius", Rep. of Macedonia

Introduction

A series of article published during the past decade indicated the potential of Doppler sonography for improving the sonographic assessment of renal dysfunction. Ultrasonic duplex scanning of the renal artery is a non-invasive method for screening and diagnosis of renovascular hypertension (1). This method may also be useful for the evaluation of parenchymal renal damage caused by hypertension, making use of flow velocities, the resistive index and the pulsatility index (2).

Previous study have shown that the increased renal resistive index (RRI) is associated with early signs of target organ damage in essential hypertension and could be a reliable marker of intrarenal moderate and severe vascular damage (nephroarteriosclerosis and atherosclerosis), (3,4).

In the present study, we examined the relationship between RRI and other markers of renal function in patients with mild-to-moderate essential hypertension. In addition, we assessed the relationship between RRI and hypertensive end-organ damage, including electrocardiograms and fundoscopic changes.

Study Design and Methods

In order to evaluate the importance of RRI as a predictor of renal vascular and target organ damage in case of mild to moderate essential hypertension, 40 untreated patients,

divided in two groups were examined: group 1, 18 men (mean age 43.11 ± 7.72), and group 2, 22 women (mean age 49.22 ± 8.91). All patients underwent complete physical examination and routine biochemical analyses. Creatinine, blood urea nitrogen, uric acid, triglycerides, total and high and low (LDL) density lipoprotein (HDL)-cholesterol, and other standard biochemical evaluation were performed on serum according to routine methods. Intrarenal RI values were obtained using Color Duplex Doppler echosonography from intraparenchymal arteries, either the arcuate or interlobar arteries of both kidneys and mean value was taken for analysis. We also studied the relationship between RRI and other markers of renal function and as well as evaluation of the presence and extent of other kinds of hypertensive target organ damage (fundoscopic and electrocardiograms changes). Body mass index (BMI) was calculated using the formula: $BMI = \text{weight (kg)} / \text{height (m)}^2$. Creatinine clearance was calculated using Cocroft&Gold formula.

Electrocardiograms and fundoscopy changes were evaluated by conventional codex (ECG: 0-no abnormality, 1-levonentricular hypertrophy; 2-ST-T changes; fundoscopy: 0: no abnormality, 1: 1st degree and 2: 2nd degree of hypertensive retinopathy by KWB).

Table 1. Clinical characteristics of study patients

	Men	Range	Women	Range	p
N	18		22		
SBP, mmHg	162.11 ± 15.17	130-190	167.04 ± 16.80	140 - 210	N.S
DBP, mmHg	105.50 ± 5.06	100-115	106.50 ± 4.82	95 - 115	N.S
Age, years	43.11 ± 7.72	28-53	49.22 ± 8.91	29 - 64	0.01
BMI, kg/m ²	28.32 ± 3.09	23-35.4	33.55 ± 5.04	21.60 - 40.7	0.000
Glucose/S, mmol/L	5.04 ± 0.75	3.4-6.3	5.57 ± 0.65	3.9 - 6.8	0.02
Uric acid/S, $\mu\text{mol/L}$	345.66 ± 109.1	170-543	296.63 ± 78.70	211 - 492	N.S
BUN, mmol/L	6.52 ± 1.82	3.5-9.9	5.31 ± 1.49	2.8 - 8.6	0.03
Creatinine/S, $\mu\text{mol/L}$	89.27 ± 12.32	74-110	67.09 ± 2.90	48 - 98	N.S
Cr Clearance, ml/min*	114.77 ± 19.31	92-155	123.55 ± 0.98	72 - 179	N.S
Triglycerides	2.02 ± 1.13	0.90 - 4.6	1.82 ± 0.87	0.9 - 4.7	N.S
Total cholesterol	5.37 ± 1.18	3.0-7.9	6.31 ± 0.81	5.2 - 8.8	0.003
LDL cholesterol	3.67 ± 0.74	2.3-5.4	4.27 ± 0.85	2.4 - 6.5	0.01
HDL cholesterol	0.99 ± 0.27	0.50-1.50	1.23 ± 0.30	0.8 - 2.1	0.01
RRI	0.61 ± 0.06	0.46-0.70	0.63 ± 0.04	0.55 - 0.72	N.S

All data are presented as mean \pm SEM. * Calculated using Cockcroft's formula.

All data are expressed as means \pm SEM. Differences between variables were assessed using the appropriate statistical tests based on the underlying distribution of the variable. Differences between prevalence's were assessed by χ^2 test or Fisher's exact test as appropriate.

Results

Clinical characteristics of study patients are reported on Table 1. All examined patients were over weighted: BMI=28.32 \pm 3.09 for man and 33.55 \pm 5.4 for women. There was no difference of blood pressure and RRI between the groups. In 16 out of 40 patients (40%) increases of RRI (>064) was found (Fig. 1).

Figure.1: Renal Resistive Index (>0.64) in examined patients

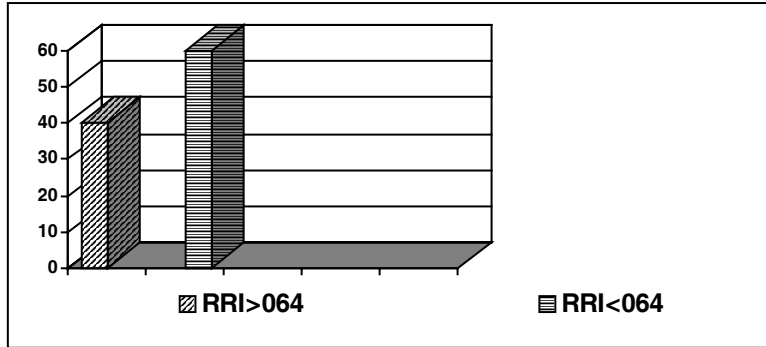
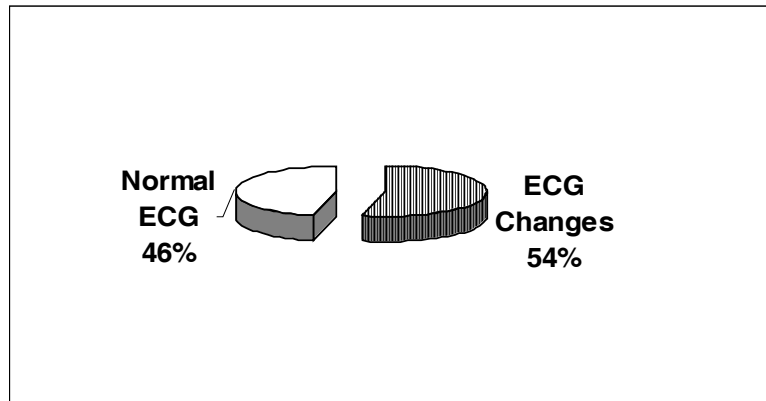


Figure 2 and 3 shows the relationship between RRI and other types of hypertensive target organ damage. Namely, the incidence of abnormal RRI was higher in hypertensive

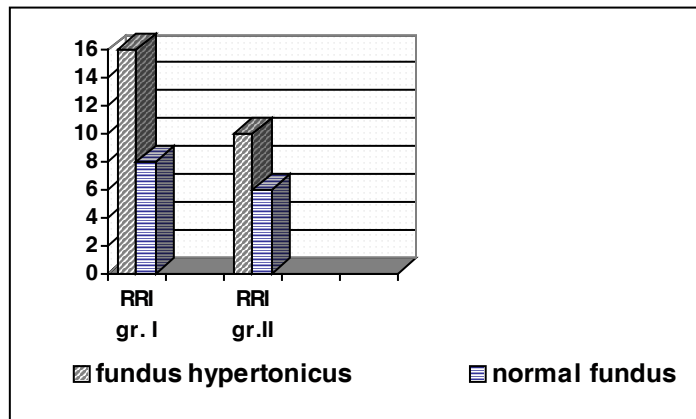
patients with abnormal ECG than in those with normal ECG (in 9 out of 16 (53.7%) of patients with increases RRI have electrocardiograms hypertensive changes (Fig 2).

Figure 2. Hypertensive electrocardiograms changes in both groups



Also, abnormal RRI was more often found in patients with hypertensive damage on funduscopy (Fig.3).

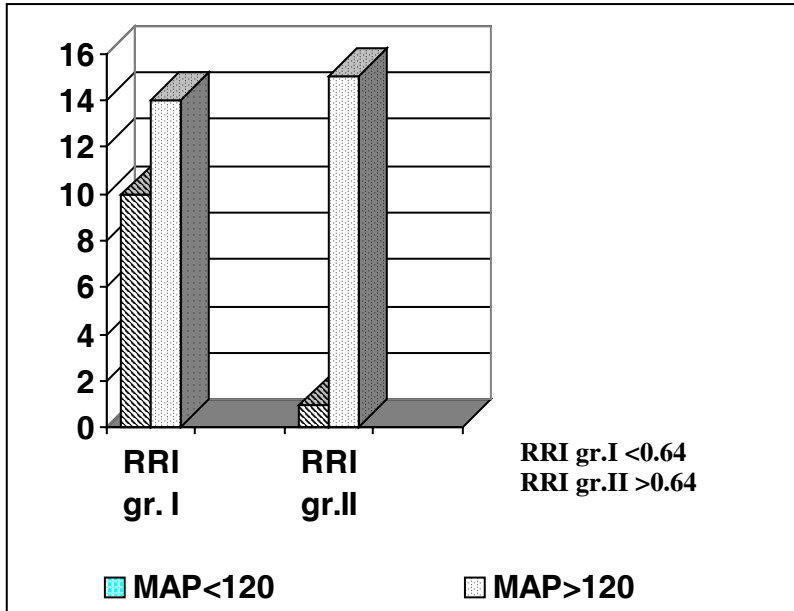
Figure 3. Presence of fundus hypertonicus in relation to the level of the Renal Resistive Index (Gr.I=RRI<064 and with Gr.II=RRI >064)



No correlation between RRI and systolic (SBP) and diastolic (DBP) blood pressure was found. RRI showed significant correlation with mean arterial pressure (MAP),

$p < 0.019$, using χ^2 -Fisher exact test), but not with other investigated parameters (Fig.4).

Figure 4: Level of Mean Arterial Pressure in relation to the level of Renal Resistive Index (χ^2 test, $p=0.019$)



Significant correlation of SBP with age, serum uric acid, cholesterol and electrocardiograms changes was found, but not with RRI.

Discussion

Ultrasonic duplex scanning is an established method for the diagnosis of renovascular hypertension (1). Thus, US Doppler has proved to be a useful non-invasive tool for evaluating renal vasculature in several different pathological conditions such as acute renal failure, acute and chronic renal graft rejection, diabetic nephropathy (5, 6).

A series of articles published during the past decade indicated the potential of Doppler sonography for improving the sonographic assessment of renal dysfunction. The Doppler RI (peak systolic velocity-end diastolic velocity/peak systolic velocity) was advanced as a useful parameter for quantifying the alteration in renal blood flow that may occur with renal disease.

Several study have shown that a normal mean renal RI is approximately 0.60. The largest series to data reported a mean±SD RI of 0.60±0.01 for subjects without preexisting renal disease. Three prior studies also reported normal mean RI value of 0.64±0.05 (7). In general, most sonographers now consider 0.70 to be the upper threshold of the normal RI in adults. In our study we found the upper normal limit of RRI to be 0.64.

An increase in the RRI has been reported to be related to macro vascular arteriolar and glomerular sclerosis as well as the presence and extent of interstitial damage in renal parenchymal disease (8).

Increased renal resistance detected by ultrasound Doppler has been reported in severe essential hypertension and recently was shown to correlate with the degree and duration of renal impairment in hypertensive patients with chronic renal failure (5, 6). However, the pathophysiological significance of these findings is still controversial.

More recently, an increased RI has been reported to be related to macro vascular atherosclerotic damage in hypertensive diabetic patients, to increased BP and to duration of disease in patients with essential hypertension, suggesting that it could reflect intraparenchymal arteriolar damage and could serve as a prognostic marker of hypertensive renal injury (9, 10).

Pontremoli et al.(3) showed that the RRI positively correlated with SBP and age as well as with signs of early end organ damage, and negative correlation between RRI, renal volume and diastolic BP. Renal vascular resistance is significantly and independently influenced by age, gender, urinary albumin excretion and systolic BP.

In our study no difference was found between RRI and gender, RRI was not correlated with SBP, DBP and age. RRI showed positively correlation with mean arterial pressure, $p < 0.019$, reported in previously studies (10, 11).

In the hypertensive patients RRI correlated with creatinine clearance and BUN, but not with serum creatinine, and also RRI increases in patients with hypertensive end organ damage (4). In the present study, we found a higher incidence of abnormal RRI in patients with moderate or severe hypertensive retinopathy and ECG abnormalities. Moreover, abnormal RRI was more frequently found in

patients with diabetes than in those without. On the basis of these findings, abnormal RRI appears to be associated with multiple types of organ damage caused by hypertension, further supporting the utility of RRI as an indicator of target organ damage in essential hypertension (11).

The present study shows that increased Doppler renal RI is associated with early hypertensive end organ damage, namely electrocardiograms and funduscopy changes in patients with mild-to-moderate essential hypertension.

Conclusions

In opposite to previously presented findings, our results suggested that RRI couldn't be an early marker of renal vascular damage in mild essential hypertension.

In addition, increased RRI may be associated with multiple type of end-organ damage (such as funduscopy and electrocardiograms changes) and could be a reliable marker for target organ damage and predictor of progression of renal damage in patients with moderate to severe hypertension according of severity, duration and treatment of hypertension.

Thus, noninvasive evaluation of RRI may be useful for the detection of earlier

target organ damage in mild to moderate essential hypertension and renal atherosclerosis in patients with moderate to severe hypertension.

References

1. Handa N, Fukunaga R, Uehara A et al. Echo-Doppler velocimeter in the diagnosis of hypertensive patients; the renal artery Doppler technique. *Ultrasound med Biol* 1986;12:945-952
2. Mostbeck GH, Kain R, Mallek R et al. Duplex Doppler sonography in renal parenchymal disease. *J Ultrasound Med* 1993;12:215-219
3. Pontremoli Roberto et al: Increased renal resistive index in patients with essential hypertension: a marker of target organ damage. *Nephrol Dial Transplant*. 1999; 14:360-365
4. Shimizu Yoshiomi et al: Clinical Usefulness of Duplex Ultrasonography for the Assessment of Renal Arteriosclerosis in Essential Hypertensive Patients. *Hypertens Res* 2001;24:13-17
5. Stevens PE, Gwyther SJ et al. Non invasive monitoring of renal blood flow characteristics during acute renal failure in man. *Intensive Care Med* 1990;16:153-158
6. Stevens PE, Gwyther SJ et al: Interpretation of Duplex Doppler ultrasound in renal transplants in early postoperative period. *Nephrol Dial Transplant* 1993; 8:255-258
7. Norris C, Pfeiffer J, Rittgers S, Barnes RW. Non invasive evaluation of renal artery stenosis and renovascular resistance: experimental and clinical studies. *J Vasc Surg* 1984;1:192-201
8. Mostbeck G, Kain R, Mallek R et al. Duplex Doppler sonography in renal parenchymal disease: histopathologic correlation. *J Ultrasound Med* 1991; 10:189-194
9. Boeri D, Derchi LE, Martinoli C et al. Intrarenal arteriosclerosis and impairment of kidney function in NIDDM subjects. *Diabetologia* 1998;41:121-124
10. Veglio F, Provera E, Pinna G et al. Renal resistive index after captopril test by Echo-Doppler in essential hypertension. *Am J Hypertension* 1992;5:431-436
11. Bardelli M, Jensen G, Volkmann R, Anrell M. Non-invasive ultrasound assessment of renal artery stenosis by means of the goosling pulsatility index. *J Hypertens* 1992;10:985-989